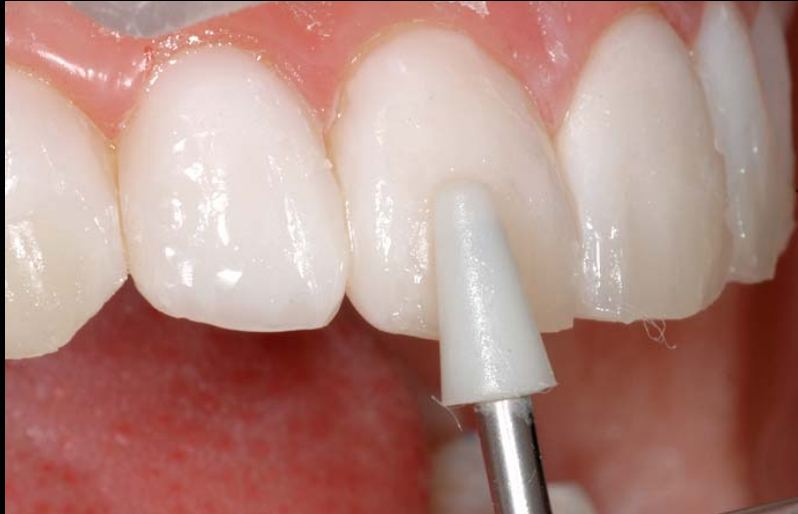

ASSESSING AESTHETIC COMPOSITE VENEER PLACEMENT VIA DIGITAL PHOTOGRAPHY

Jack D. Griffin, Jr, DMD*



Restoring teeth using direct composite veneers can be quite challenging for a clinician. Achieving natural color blending, masking dark teeth, removing decay, and providing a natural finish require meticulous placement with various composite opacities and shades. Critical self-evaluation using digital photography, documentation, and follow-up visits to perform veneer enhancements are critical to ensure an aesthetic outcome. This article will demonstrate how digital photography is used to achieve an aesthetic result in the placement of eight direct resin veneers.

Learning Objectives:

This article discusses the procedures required to place, evaluate, and finalize composite veneers in an efficient manner. Upon reading this article, the reader should:

- Become familiar with the use of digital photography to evaluate, plan, and prepare the dentition.
- Understand preparation guidelines to correct missing and misshapen teeth for conservative resin veneers using images as a guideline.

Key Words: composite, veneer, preparation, digital, camera

**Private practice, Eureka, MO.*

*Jack D. Griffin, Jr, DMD, 18 Hilltop Village Center Drive, Eureka, MO 63025
Tel: 636-938-4141 • E-mail: Esmilecenter@aol.com*

Porcelain and composite restorations have been widely used over the past 20 years to create highly aesthetic smiles. Replacing missing tooth structure can be successfully achieved with minimal tooth reduction as long as concepts in smile design, tooth preparation, and material limitations are understood.¹⁻³ While composite veneers may be the greatest expression of creativity and artistic ability among clinicians, direct resin techniques can be difficult to perfect.⁴ Contemporary composite systems provide clinicians with materials of varying shades and opacities that can mimic natural tooth structure when used in smile enhancement.⁵ As demonstrated in this presentation, the key to a successful outcome is knowing when to use the different composites in each tooth, objectively evaluating placement, and then making necessary corrections. Photography and self-evaluation are critical adjuncts in direct veneer placement (Table).

Simplifying Composite Selection

Many of the resin systems (eg, Renamel, Cosmedent, Chicago, IL; Filtek Supreme Plus, 3M Espe, St. Paul, MN; Esthet-X, Dentsply Caulk, Milford, DE) available today have at least three opacities of composite, an important requisite when life-like veneers are desired.⁶ The key is knowing where to place each layer and in what shade to obtain consistent and natural results. Dentin composites have more opacity than other composites and are used for three basic reasons: to replace missing dentin, to add length or width to the tooth, and to conceal darker tooth colors. As a result, they efficiently block unwanted light transmission when the clinician is performing length or width additions or covering transition areas within the restoration (eg, when hiding the edge of a fracture). Since these dentin materials are typically microhybrids, they possess the strength needed to withstand occlusal forces in the intraoral environment.^{7,8}

Table

Clinical Uses for Photography in a Composite Veneer Case

- Pre-treatment: Planning the case;
- Mid-treatment: Scrutinizing placement, anatomy, and finish. Using as a framework for making adjustments; and
- Post-treatment: Evaluating material and technique performance.

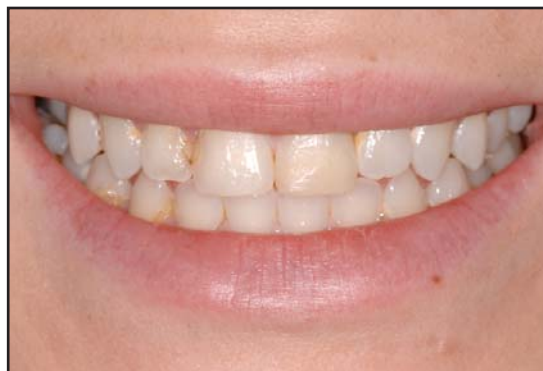

Figure 1. The lip line covered all of the gingiva except for the points of the papilla. Both porcelain and composite veneers were offered to the patient.

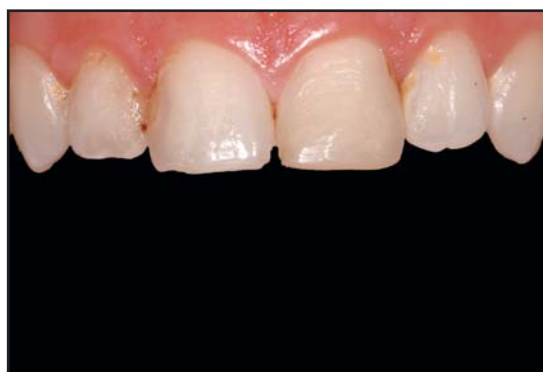

Figure 2. Decay and composite material must be completely removed prior to composite placement.

Incisal shades are strategically used in small amounts to mimic translucency and incisal characterization or to enhance the surface of the entire restoration. Since these composites have little opacity, they cannot be used to conceal a color or transition area. If used properly, however, they will give the restoration a natural appearance. Enamel composites basically fall between dentin and incisal in terms of opacity and their ability to mask color. They form the majority of the facial surface of the tooth and are used to form the basis of the final desired tooth shade. Their color intensity is influenced by the thickness of the resin layer and by any color that might be underneath it. The thicker it is—this also applies to dentin shades—the more intense and consistent its final shade will be. These are the basic components necessary for the clinician to create highly aesthetic composites using a direct layering technique. While varying tints and customization materials are often needed when matching a single tooth, they are seldom required for a complete veneer case.

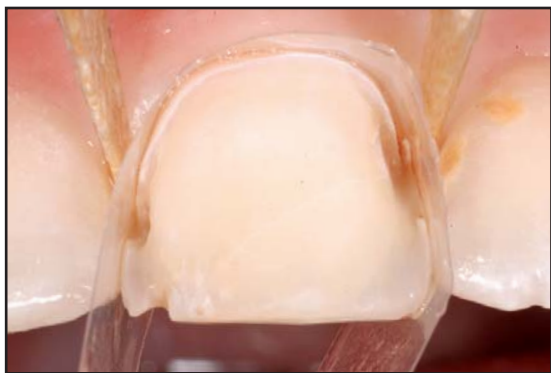

Figure 3. Decay, composite, and surface stains are removed, and the entire surface is roughened with a diamond bur. A contour matrix is placed and very lightly wedged.

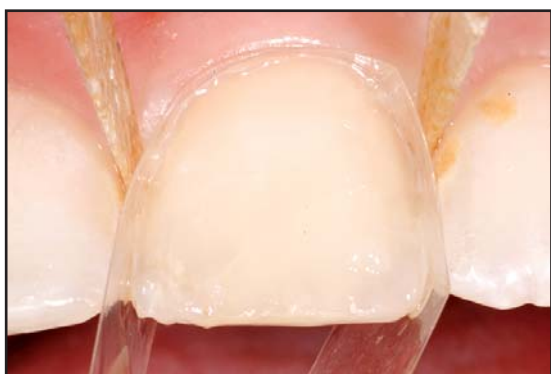

Figure 4. The areas of missing tooth structure interproximally and incisally are replaced with a microhybrid matching the existing dentin shade.

Patient Examination and Treatment Planning

A 24-year-old female presented with an unaesthetic smile. Comprehensive clinical examination revealed failing restorations, recurrent decay, marginal leakage, and staining. Her basic tooth color was A2 to A3, with a moderate amount of incisal translucency (Figure 1). A full series of intra- and extraoral images were taken for treatment planning, marketing, and case documentation. These images were studied—along with clinical examination notes—prior to treatment so that a basic plan could be formulated. After viewing an office-generated PowerPoint slide show displaying different treatment options, the patient chose a final tooth shade that was the darkest bleach shade (ie, OM3). While treatment plans were made for porcelain and composite veneers, the patient selected composite restorations due to financial reasons. Lateral smile views demonstrated that the anterior 10 teeth would require veneers from second premolar to premolar for a smooth, natural-appearing, enhanced smile, but only eight were requested by the patient.

Treatment would involve veneering the teeth to lighten their color as well as repairing the decayed areas (Figure 2). The patient was scheduled for a 90-minute appointment to place the eight composite veneers with a 50-minute follow-up three days later.

Composite Veneer Technique

Following anesthetization and tooth isolation, various shades of composite were tried on the teeth to evaluate color and masking ability. It was important to begin this assessment on a central incisor to establish proper mid-line, cant, color, and proportion. When done correctly, it would be much easier to establish the proper size, shape, and alignment of the surrounding teeth.

The existing composite resin was removed from #9(21) with a coarse diamond bur, and all interproximal filling material and decay were removed with carbide burs. Caries indicator (ie, Sable Seek, Ultradent Products, South Jordan, UT) was used to verify complete caries elimination. The face of the tooth was roughened with a diamond bur, and a slight finish line was created just below the gingival margin. A contoured anatomical matrix was placed and wedged loosely (Figure 3). The matrix extended slightly into the sulcus and provided the smoothest possible surface to finish the composite.⁹ After the tooth was etched with 38% phosphoric acid, it was rinsed thoroughly, and a dentin bonding agent was applied and air thinned.

The first composite resin layer (ie, Renamel Universal Hybrid, Cosmedent, Chicago, IL) formed the foundation of color within the restoration (Figure 4). Shade A3 was placed in the formerly decayed interproximal areas and on the incisal edges where length was to be added. It was undercontoured by 1 mm in all areas so that the layer would not extend through the final enamel layer

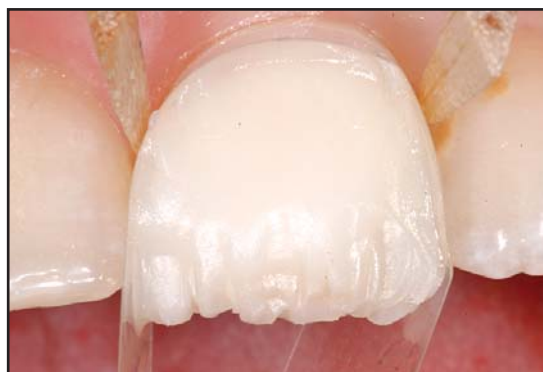

Figure 5. The enamel microfill composite is placed with a plastic instrument and shaped with a composite roller after the flowable composite.

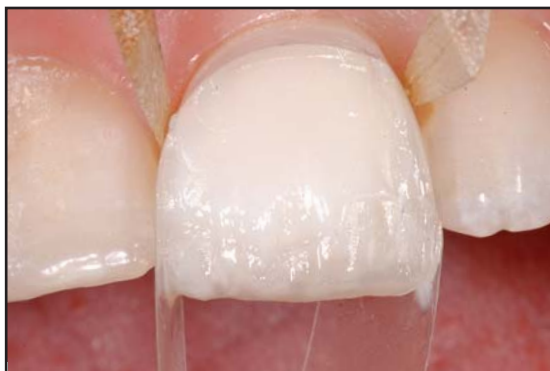

Figure 6. Low opacity incisal shade is added and shaped about 1 mm longer than the final desired length to allow for anatomy development and polishing, and is then cured.

after finishing, and then cured for 20 seconds. The enamel layer was initiated with the placement of a flowable composite along the gingival aspect of the matrix and followed with a bleach-shade (SB3) composite. The noncured flowable composite reduced voids and was mostly forced out as the more viscous enamel material was placed. The incisal edge was made irregular with the edge of a plastic instrument or explorer and left 1 mm to 2 mm from the desired final edge length, and was then cured for 20 seconds (Figure 5). The key was that the indentations were varied in width and length, so that the incisal shade blended naturally into the enamel without abrupt transition areas. A transparent incisal shade of flowable composite was followed by incisal-shaded composite that was shaped and cured (Figure 6).

When the matrix was removed, a bulk of material at the gingival aspect extended just beneath the gingiva, where the smooth surface produced by the matrix would remain largely untouched. The excess material and basic shaping were eliminated with a finishing diamond bur, and the midline, cant, and tooth proportion were adjusted (Figure 7). Working distally from the midline, the other teeth were built around the colors and contour of this tooth (Figure 8). Basic contouring was performed with a finishing diamond bur. A #12 blade composite knife, #7901 finishing bur, and sand paper disks (ie, Sof-Lex Brush, 3M Espe, St. Paul, MN) were used for basic contouring. Curing was performed for an additional 20 seconds from the facial and lingual surfaces. A full series of intra- and extraoral images were captured before patient dismissal so that a critique could take place. Additional polishing and shaping were completed three days later at the enhancement appointment.

The digital images were loaded onto the computer, scrutinized, and marked with needed changes (Figure 9).

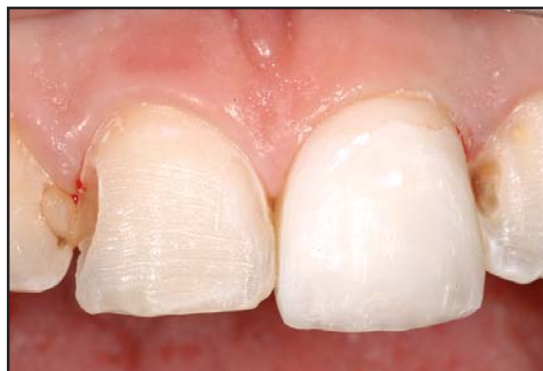

Figure 7. A basic shape is formed with a finishing diamond bur. The critical part is achieving a proper position and cant to the midline and a suitable tooth width.

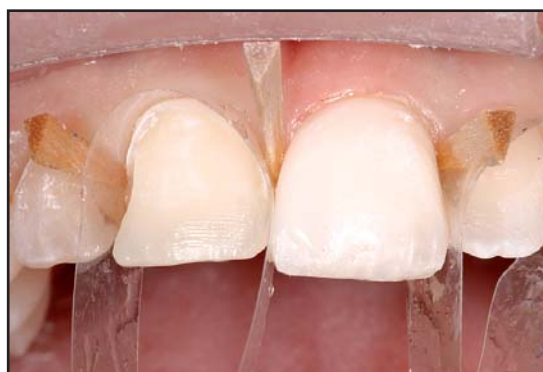

Figure 8. The neighboring teeth can then be completed using the same techniques as before.

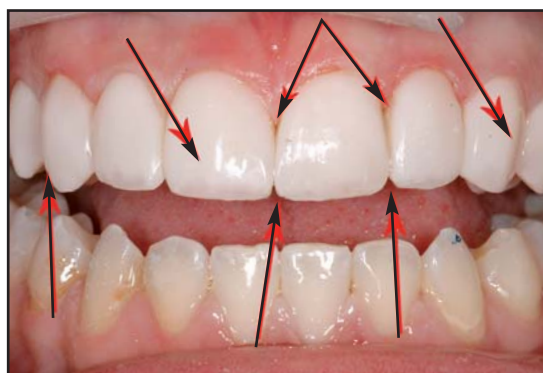


Figure 9. Marks can be made in a variety of ways to point out places that need correcting, so that areas requiring improvement are not overlooked.

The resulting composite veneers were objectively evaluated by the clinician, who viewed them critically without the distractions of the operator. These images were then placed on the operator monitor for chairside reference. Other images were printed and placed behind the patient to form an outline, so that needed enhancements could be completed in an orderly manner.

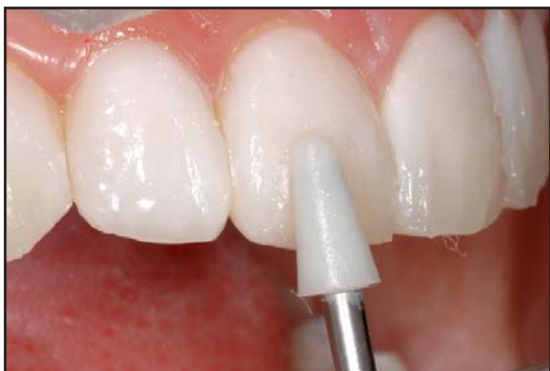

Figure 10. The composite roller makes smoothing and contouring final layers very efficient.

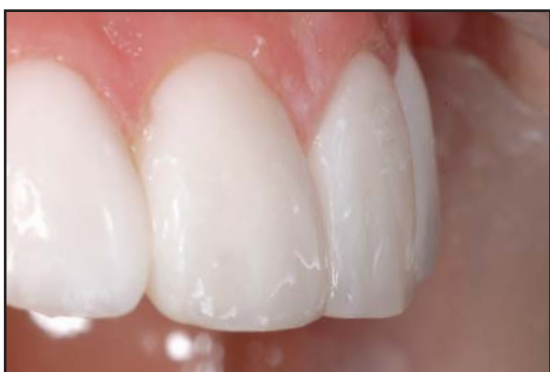

Figure 11. Care is taken to keep anatomy on the facial surface during contouring and polishing.

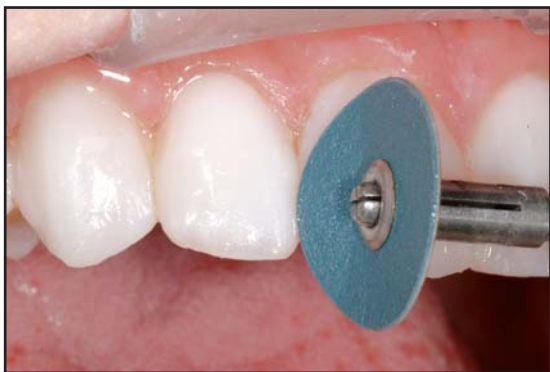

Figure 12. Flexible sand paper disks are used to shape embrasures between teeth and for basic tooth contouring.

Enhancement Appointment

At the three-day follow-up appointment, the veneers were evaluated for areas that were rough, sharp, or unable to be flossed. Phonetics were also used to determine if the incisal edge position required adjustment. The patient was shown the images taken from the placement appointment and decided to have the second premolar veneered

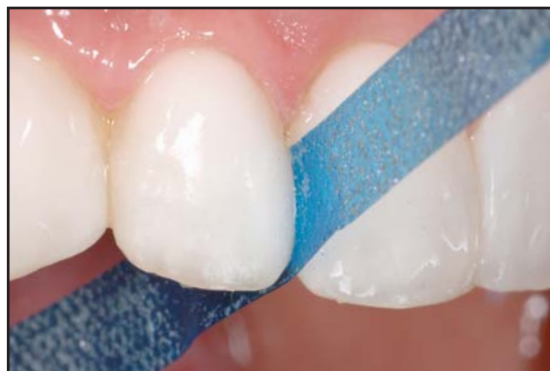

Figure 13. Interproximal surfaces are then contoured and smoothed with a #12 blade and finishing strips.

as well, since they were clearly visible in the photographs. Areas that required additional composite were modified first via diamond roughening and sand blasting with $27\ \mu\text{m}$ silica, followed by etching and the application of a bonding agent. Composite was placed to correct voids, dark color that was visible, and/or insufficient contours. A plastic instrument was used to place the material and was smoothed and formed with a composite rolling instrument (ie, CompoRoller, Kerr Corporation, Orange, CA) (Figures 10 and 11). Embrasures were shaped and refined with three levels of finishing disks, and interproximal areas were shaped with a composite knife and abrasive strips (Figures 12 and 13). Care was taken to enhance facial anatomy by developing subtle developmental indentations and by beveling the incisal third back toward the lingual, which was accomplished with rubber polishing cups and disks (Figure 14). The last step included a felt wheel with polishing paste in order to achieve a high luster (Figure 15).¹⁰ As the patient desired that her mandibular teeth matched the light color of the maxillary teeth, take-home bleaching (ie, Nite White ACP, Discus Dental, Culver City, CA) was recommended.

Postoperative Images

An additional follow-up appointment was made three weeks later, and a full series of digital images were captured to be used for case evaluation, legal documentation, and practice promotion. A portrait image was critical not only for marketing, but also for final case evaluation of technique and materials. Final midline position and cant were verified and archived in the office portfolio. A full smile revealed consistent color and lifelike incisal characteristics (Figure 16). The patient continued to bleach her mandibular teeth, and the shade lightened enough to closely match the shade used on the maxillary composite veneers.

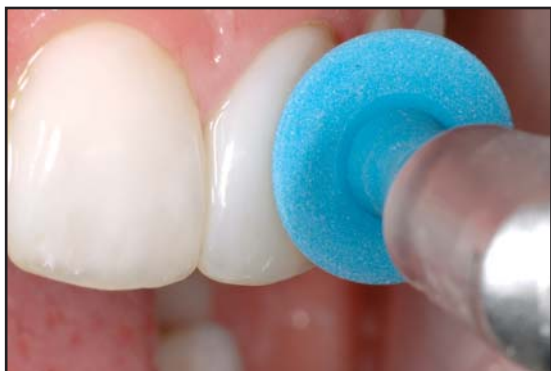

Figure 14. Rubber polishing disks are then used to finish the polish and to enhance developmental grooves on the facial and incisal characteristics.

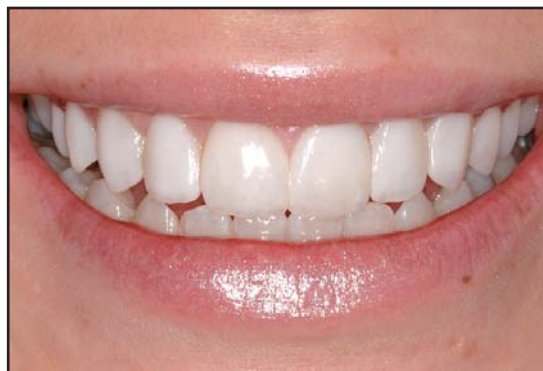

Figure 16. By using various opacities and colors, the veneers cover all of the decayed and broken down areas and the new surface color is consistent and natural.

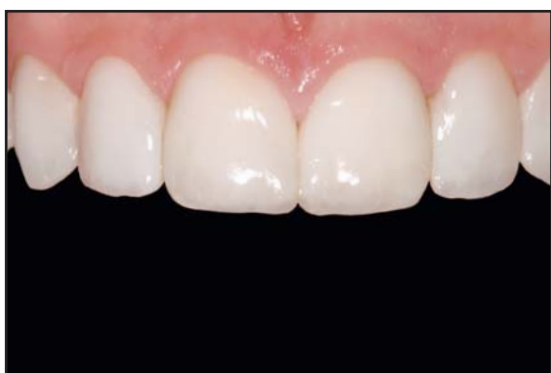

Figure 15. After three weeks, final images are taken that are consistent with the preoperative views.

Discussion

Office commotion, lighting, patient positioning, and even doctor fatigue can make the evaluation of a procedure much more difficult to do chairside than on a large monitor in a dark room separate from the operator. An image of the full frontal view of the smile is used to check midline, cant, buccal corridor development, and other important factors. Full intraoral images from the front and sides can be used to check shade and character consistency, embrasures, surface texture, and basic shape to locate any deficiencies that might appear in the veneers. These deficiencies include areas of bulkiness, improper embrasures, poor contours, unreal surface texture, and inconsistent colors. Photography makes the defects and needed corrections apparent.

Conclusion

A realistic characterization of the teeth was achieved by efficiently using different opacities of composite and placement in layers. Although composite veneers require

more chairside effort than porcelain veneers and may require more maintenance, they can be rewarding for the dental staff and a cost-effective confidence builder for the patient. In addition, composite veneers allow the clinician to express his or her creativity and artistic ability. Direct resin techniques, however, can be difficult to master; therefore, by using photography as a form of evaluation throughout treatment, the patient will be ensured a superior aesthetic smile.

Acknowledgment

The author declares no financial interest in any of the products, materials, or suppliers referenced herein.

References

1. Milnar F. A minimal intervention approach to the treatment of a Class IV fracture. *J Cosmet Dent* 2006;21(4):106-112.
2. Christensen GJ. Bonding to dentin and enamel where does it stand in 2005? *J Am Dent Assoc* 2005;136(9):1299-1302.
3. Terry DA. Direct composite resin restoration of adolescent Class IV tooth fracture: A case report. *Pract Periodont Aesthet Dent* 2000;12(1):23-29.
4. Fahl N. The direct/indirect composite resin veneers: A case report. *Pract Periodont Aesthet Dent* 1996;8(7):627-638.
5. Vargas M. Conservative aesthetic enhancement of the anterior dentition using a predictable direct resin protocol. *Pract Proced Aesthet Dent* 2006;18(8):501-507.
6. Miller M. *Reality* 2006. Vol 20. Houston, TX: Reality Publishing; 2006.
7. Chyz G. Postorthodontic restoration of worn incisal edges. *Contemp Esthet* 2006;10(4):36-39.
8. Fahl N. Achieving ultimate anterior esthetics with a new micro-hybrid composite. *Compend Contin Educ Dent* 2000;26(suppl):4-13.
9. Belvedere PC. Direct bulk placement for posterior composites using an anatomically shaped clear matrix creating true anatomic interproximal surfaces. *J Indiana Dent Assoc* 2006;85(1):14-18.
10. Peyton JH. Finishing and polishing techniques: Direct composite resin restoration. *Pract Proced Aesthet Dent* 2004;16(4):293-298.

CONTINUING EDUCATION (CE) EXERCISE No. X



To submit your CE Exercise answers, please use the answer sheet found within the CE Editorial Section of this issue and complete as follows: 1) Identify the article; 2) Place an X in the appropriate box for each question of each exercise; 3) Clip answer sheet from the page and mail it to the CE Department at Montage Media Corporation. For further instructions, please refer to the CE Editorial Section.

The 10 multiple-choice questions for this Continuing Education (CE) exercise are based on the article "Assessing aesthetic composite veneer placement via digital photography," by Jack D. Griffin, Jr, DMD. This article is on Pages 000-000.

1. Clinical dental photography can be used BEFORE a direct composite veneer case to do which of the following?
 - a. Help plan the case with regard to tooth preparation and material choice.
 - b. Have images to help create an office portfolio of "before" and "after" images.
 - c. Document the case for liability reasons.
 - d. All of the above.
2. Which of the following is important in choosing a composite for direct veneers?
 - a. Packaging in unidose compules.
 - b. Using a system with varying composite opacities for natural variation of translucency.
 - c. Having a single universal composite that can be used on the tooth to replace both dentin and enamel for efficiency.
 - d. Employing incisal shades to mask underlying darker colors in the tooth.
3. Which of the following composite components is used for masking color or for matching more opaque parts of the tooth?
 - a. Dentin shades.
 - b. Enamel shades.
 - c. Incisal shades.
 - d. Stumpf shades.
4. Which of the following is an instrument that can aid in final composite placement and contouring?
 - a. A composite roller.
 - b. A composite knife.
 - c. Composite photo.
 - d. A microbrush.
5. Why is photography valuable after composite placement?
 - a. To honestly evaluate veneer placement.
 - b. To form a plan for needed refinement.
 - c. To be printed or placed on an operatory monitor for reference during veneer enhancements.
 - d. All of the above.
6. Which of the following represents a type of matrix that is precontoured, helps retract tissue, and forms the basic composite shape interproximally and gingivally?
 - a. Straight celluloid strip.
 - b. Automatrix.
 - c. Gingival retraction paste.
 - d. Contour matrix.
7. When there is interproximal decay that must be restored, what is the first material chosen and placed in the interproximal area?
 - a. A dentin shade that matches the existing dentin color.
 - b. An enamel shade that is the desired final tooth shade.
 - c. An incisal shade that mimics incisal character.
 - d. Custom staining to create internal character.
8. Flowable composite is placed in the matrix...
 - a. And is cured before adding any other material to provide a strong composite base.
 - b. And is left uncured so that it is forced out by the more viscous composite, which may reduce voids.
 - c. To seal the matrix from salivary contamination.
 - d. To increase bond strength of the composite.
9. Which tooth should be treated first in a direct composite veneer case to establish cant, midline, and tooth proportion?
 - a. Central incisor.
 - b. Lateral incisor.
 - c. Canine.
 - d. Milk tooth.
10. Which of the following criterium/criteria must be followed when doing final facial polishing?
 - a. Achieve a natural polished surface that will resist staining and plaque accumulation.
 - b. Preserve facial anatomy and avoid creating an unnaturally flat surface.
 - c. Create embrasures that are well polished and proportionally placed.
 - d. All of the above.